

CAD/CAM expands the scope of restorative dentistry

Author_ Manfred Kern, Germany

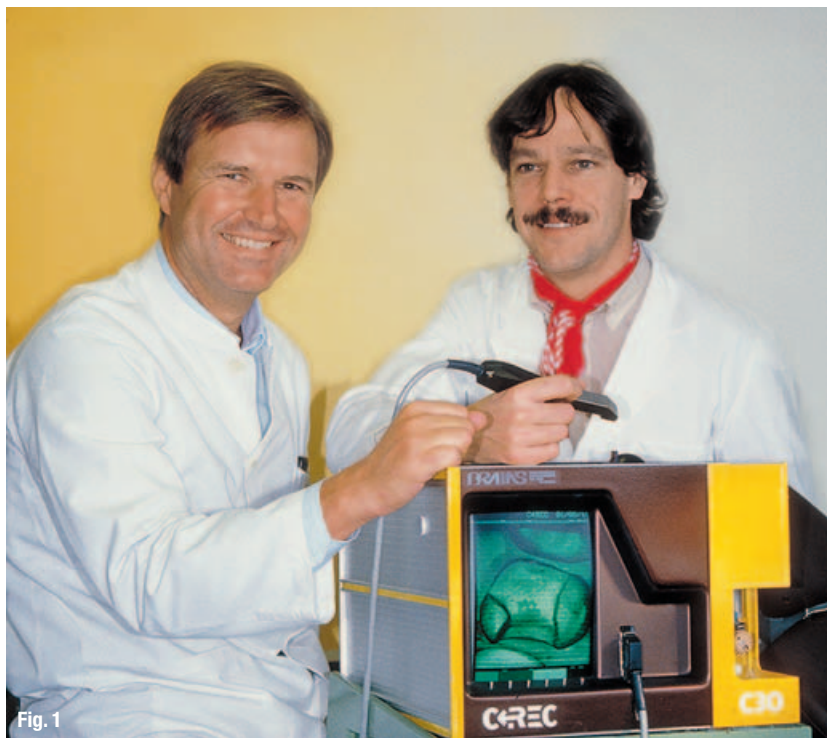

Fig. 1

Fig. 1 Prof Werner Mörmann and Dr Marco Brandestini in 1985 with the CEREC 1 prototype. (Photo: Prof Werner Mörmann/Quintessenz)

Today, it is impossible to imagine dentistry without digital technology and CAD/CAM procedures. Intra-oral and extra-oral measuring, the scanning of antagonists and bite registrations, 3D design on a computer, the availability of countless tooth shapes in a dental database, the creation of anatomically shaped occlusal surfaces, functional articulation on a virtual model, the subtractive machining of high-performance ceramics—all this would be impossible without computers.

The groundwork for this quantum leap was laid in Switzerland in 1985. For the first time ever, a 3D optical impression of a prepared tooth was acquired using an intra-oral video camera (triangulation measuring technique) and then transferred to a computer.¹ Using a computer, special imaging software and a CNC milling unit, Prof Werner Mörmann and Dr Marco Brandestini from Zurich University created the first CAD/CAM inlay from a silicate ceramic material (Fig. 1). This development was occasioned by Prof Mörmann's unpromising experiments with occlusion-borne composite inlays as a substitute for amalgam.

Owing to the high degree of polymerisation shrinkage, these inlays required extensive machining, did not fit exactly to the inner surfaces, and displayed large tolerances at the margins. In addition, Prof Mörmann wished to use ceramic on account of its similarity to natural enamel and dentine. Only with the aid of computer-controlled profile-grinding and milling machines was it possible to mill silicate ceramics (and later oxide ceramics) subtractively for highly aesthetic restorations—restorations that displayed constant and reproducible material characteristics, as well as scope for cost optimisation. The broad acceptance of dental CAD/CAM procedures is evident from the more than 20 million all-ceramic restorations (chairside plus labside) that have been produced worldwide.

Adhesive bonding furthered the development of CAD/CAM restorations

Two factors played a role here. The first factor was the desire of proponents of computer-aided chairside restorations to machine an industrially manufactured silicate ceramic with defined physical characteristics directly adjacent to the chair, and treat the patient in a single visit, without the need for a temporary. The second factor was the introduction of adhesive bonding, which creates a force-locked link between the ceramic restoration and the residual tooth tissue, does not display a mechanical interface and hence prevents crack-inducing tensile stresses. Since the introduction of adhesive bonding, it has been possible to apply defect-oriented and substance-conserving preparation techniques.

The combination of CAD/CAM ceramics and adhesive bonding facilitated the permanent stabilisation of seriously weakened cusps (Fig. 2). It was possible to dispense with mechanical retention in the cavity geometry because adhesive bonding guarantees an intimate link with the residual tooth. In many cases, a partial ceramic crown eliminated the need for a metal-based crown. This latter type of crown has the disadvantage that it necessitates a circular preparation (and hence the loss of healthy tooth tissue) in order to achieve the necessary retention. The mechanical strength of individually machined silicate ceramics is transferred directly to the tooth tissue.

This is particularly beneficial in the case of inlays, onlays, partial crowns and seriously weakened cusps.

Prof Mörmann's goal was to deploy CAD/CAM technology to create immediate all-ceramic restorations chairside without the need for temporaries. This goal derived from his experience that temporarily restored inlay cavities have a significantly negative influence on the integrity of the enamel. In many cases, the non-adhesively bonded temporary was positioned like a wedge in the cavity and transmitted the chewing forces to the weakened residual tooth. The applied forces also deformed weakly protected cusp walls. This resulted in cracks in the oral and vestibular enamel surfaces.

A second goal was to make use of high-strength oxide ceramics, such as aluminium oxide (Al_2O_3) and zirconium oxide (ZrO_2), and computer-controlled milling machines in order to create crown-and-bridge frameworks and hence pave the way for metal-free prosthetic treatment.

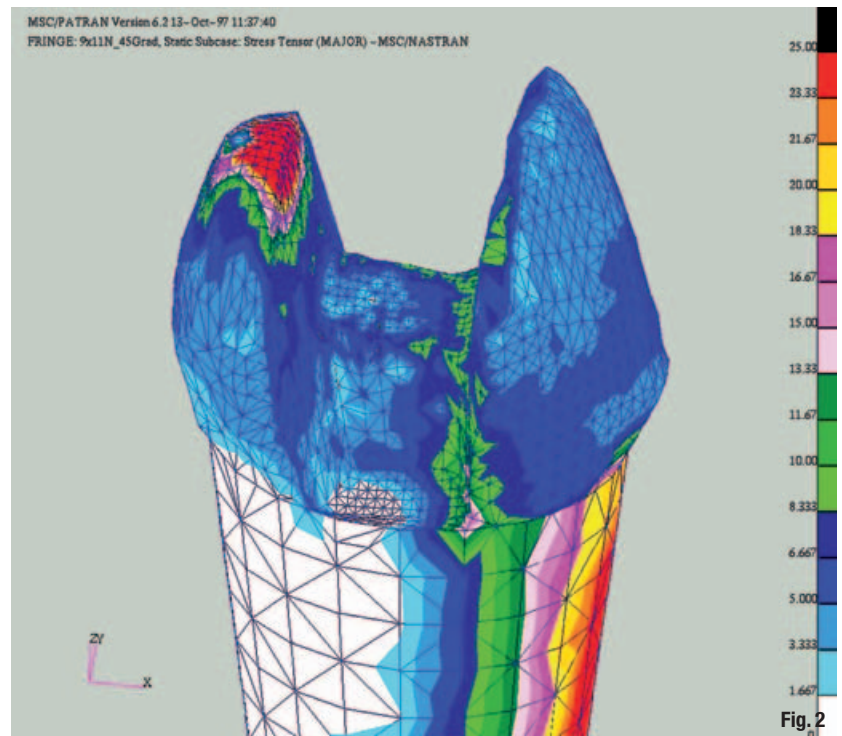
Another recent development is the online transmission of intra-oral and extra-oral digital impressions and restoration design data to external dental laboratories, which then perform the milling tasks. As a result, the dental laboratories are now more closely integrated into the work flow of dental practices.

Clinically proven

All-ceramic chairside restorations number amongst the most intensively researched dental treatment procedures. Numerous studies confirm that the clinical performance of inlays and onlays is at least comparable with that of cast-gold restorations. Durability is one of the most important evaluation criteria for ceramic materials. This underlines the importance of the study published in 2008 by Dr Tobias Otto (Aarau, Switzerland) that presented long-term clinical data going as far back as 17 years.² Since 1989, Dr Otto (one of the first CEREC users in Switzerland) has monitored 200 inlays and onlays produced using the CEREC 1 system and feldspar ceramic (VITA Mark I). These restorations were placed in 108 patients in his dental practice between period 1989 and 1991. He evaluated his findings on the basis of the modified USPHS criteria and summarised his clinical observations after 10 years and 17 years, respectively.

According to Dr Otto, 187 of the 200 restorations were still in place after 17 years. This was a survival rate of 88.7% after an average service time of 15 years (Figs. 3–5). In other words, the annual failure rate was 0.75%. Failures with Charlie and Delta ratings (USPHS) occurred between the 6th and 13th year. In most cases, these failures were attributable to ceramic fractures.

The probability of survival was significantly higher than that of layered laboratory-produced ceramic inlays and was approximately equivalent to that of alternative long-term restorations, such as cast-gold inlays, which have a survival rate of 87% after 20 years and an annual failure rate of 0.7%.³ Dr Otto established that 166 of the CEREC inlays (of an original basis of 200 restorations in 1991) were clinically intact. This is equivalent to a success rate of 83% after an average service time of 15 years. The survival rate was superior



to that established by Smales⁴ for cast inlays after 15 years (loss rate: 1.5%). It also compares favourably with the 1.3% annual failure rate established for all-ceramic, non-CAD/CAM ceramic inlays.⁵

A contributing factor is that chairside ceramic inlays can be placed immediately in a single appointment, thus eliminating the need for temporaries. In the case of conventional labside restorations, a temporary is unavoidable. Prof Roland Frankenberger established that under the influence of chewing forces, the tooth is subjected to torsional stress due to the low elastic modulus of the temporary composite material. These forces can deform inadequately protected cusp walls, cause partial fractures and incipient enamel cracking, and weaken dentine adhesion. By contrast, the immediate placement of the ceramic inlay facilitates a contamination-free adhesive bond with the hard tooth tissue and stabilises weakened cusps. The stabilising effect on the residual tooth and the existence of an adhesive bond obviously offset the consequences of wider adhesive gaps, as evidenced by long-term clinical findings.⁶

Fig. 2 Finite element measurement with the exertion of chewing forces: the ceramic inlay bears the chewing load; the tooth substance remains stress free (inlay is hidden). (Illustration: Prof Albert Mehl)

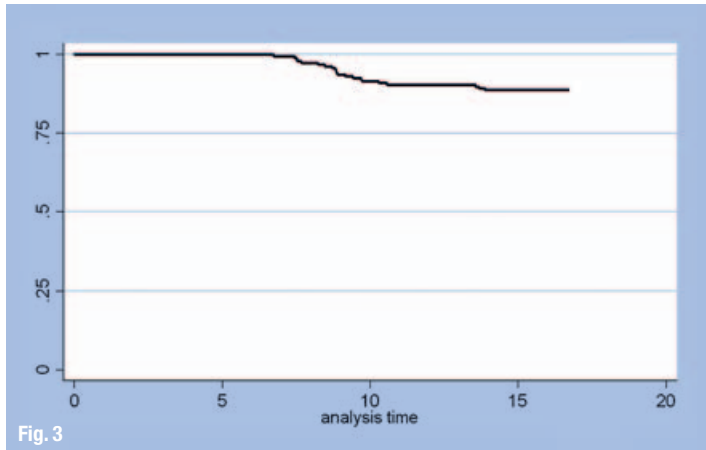


Fig. 3

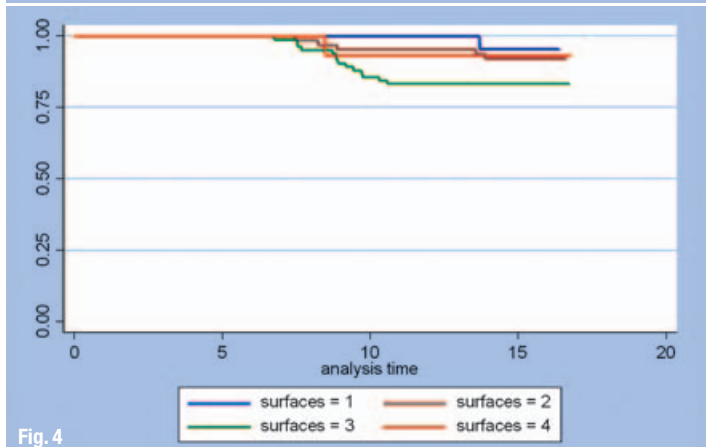


Fig. 4

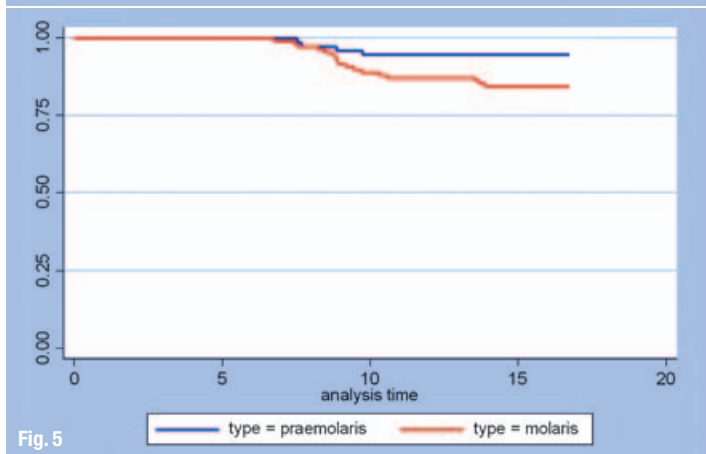


Fig. 5

composite are ignored), the Kaplan–Meier survival rate was 89% over the observation period. Dental adhesives were not yet available at the beginning of the study. If the patients are separated into two groups (that is, patients treated with and without the use of a dental adhesive), a significant difference is revealed. Without dental adhesive, the survival rate fell to approximately 80% after 16 years; with dental adhesive, the survival rate was 90%. The size of the filling did not play a role. Premolars performed better than molars. Vital teeth performed better than non-vital teeth. During the observation period, 122 events occurred. In 86% of the cases, this resulted in the loss of the restoration. Fractures (39%) were the most frequent reason for renewal.⁷

Similar findings were reported by Prof Gerwin Arnetzl. Between 1988 and 1990, Prof Arnetzl placed 358 two- and three-surface inlays made of Dicor, Optec, Hi-Ceram, Duceram and CEREC 1 (Mark I) using the adhesive bonding technique. The control group consisted of cemented gold inlays. After 15 years, CEREC and gold had a survival rate of 93%. This was significantly higher than the equivalent figure for laboratory-produced sintered ceramic inlays, which had a failure rate of 32%.⁸

Dr Reinhard Hickel and Dr Jürgen Manhart reviewed the scientific literature over a period of 10 years and calculated the annual failure rates of various materials used for Class I and II cavities. They found that CEREC restorations displayed 25% fewer failures than cast-gold fillings.⁹

A particularly interesting investigation was carried out by Dr Anja Posselt and Prof Thomas Kerschbaum, who analysed the performance of 2,328 CEREC restorations placed in 794 patients in a dental practice.¹⁰ The survival rate after 9 years was 95.5%. The filling size, tooth vitality, the prior treatment of caries profunda, the type of tooth and the location of the filling (separated according to upper and lower jaw) did not have any influence. The most common reasons for failure were tooth extractions (22.9%) and fractures (17.1%).

Dr Andreas Bindl confirmed the suitability of chairside fabrication methods for anatomically sized CEREC crowns, milled and placed in a single visit.¹¹ Various stumps were prepared for 208 feldspar ceramic crowns. After 5 years, 97% (premolar) and 94.6% (molar) of the conventionally prepared crowns (chamfer preparation) were still intact. Clinically short crowns with a reduced stump height achieved a survival rate of 92.9% (premolar) and 92.1% (molar), respectively. The failure rate for endo-crowns placed on premolars was significantly higher.

CAD/CAM ceramics conform to the gold standard

A further long-term study of the durability of CEREC restorations was published by Dr Bernd Reiss in 2006. In a private dental practice, 1,010 CEREC inlays and onlays were placed in 299 patients. After 15 to 18 years, 84.4% of these restorations were still clinically perfect (Figs. 6 & 7). Up to the end point of the study (18.3 years), no further events were observed. If the retention of the restoration is seen as the sole criterion for evaluating survival (that is, if therapeutic procedures such as trepanation and subsequent margin corrections with the aid of

Fig. 3 Survival rate (according to Kaplan–Meier) of CEREC inlays and onlays: 88.7% after maximum of 17 years. (Source: Dr Tobias Otto)
Fig. 4 Survival rate of one- to four-surface restorations (no significant difference) after maximum of 17 years. (Source: Dr Tobias Otto)
Fig. 5 Survival rates of restorations on molaris and praemolaris: CEREC restorations on praemolaris display a slightly higher success rate. (Source: Dr Tobias Otto)

Within the framework of a meta-analysis, the clinical survival probability of high-quality conservative restoration types with the respective production costs was investigated. Gold inlays and CEREC inlays had the highest success rates. The CEREC restorations perform better in terms of cost effectiveness versus durability. The higher production costs of cast-gold inlays are a disadvantage here.¹²

Biogeneric occlusal surfaces

The design of functional occlusal surfaces poses a challenge to rehabilitating the chewing function. In this area, too, CEREC has exploited advances in digital technology. IT provides valuable assistance with recreating lost tooth tissue in such a way that the restoration harmonises well with the existing dentition in terms of its structural and functional characteristics. With the aid of biogeneric modelling software, Prof Albert Mehl et al. succeeded in automatically creating patient-specific occlusal surfaces for inlays, onlays and partial crowns.¹³⁻¹⁵ In this case, the residual occlusal tooth tissue was compared with several thousand digital scans of natural occlusal surfaces contained in the CEREC tooth library (Fig. 8). The software identifies matching morphological characteristics (fissures, cusps, marginal ridges, gliding contact angle) and then inserts corresponding cusps, fossae, fissures and contact surfaces into the virtual model of the restoration. On the basis of the contact point distribution, the cusp apices and the proximal contacts, the software is capable of creating a well-matched tooth and detecting possible collisions with the bite registration. This biogeneric modelling process creates natural, individual and functional occlusal surfaces.

The extension of the CEREC indications spectrum to chairside crowns and multiple-unit labside bridges (both temporary and permanent) has placed increased demands on the intra-oral measuring process. The recently introduced CEREC AC system deploys a short-wavelength blue LED light source. In combination with the built-in anti-shake system this blue light source reduces the measurement tolerance to 19 µm in comparison with a stationary reference laser scanner.¹⁶ The preparation is optoelectronically scanned from various angles in the patient's mouth. The individual images are then combined to create complete quadrants (Fig. 9). Inadequate images are automatically detected. With a scan of the antagonists, the digital impression of the partial arch/quadrant is transmitted via a wireless link to the in-house dental laboratory. Alternatively, the data can be sent via the CEREC Connect web portal to an external dental laboratory or to an external milling centre equipped with a stationary

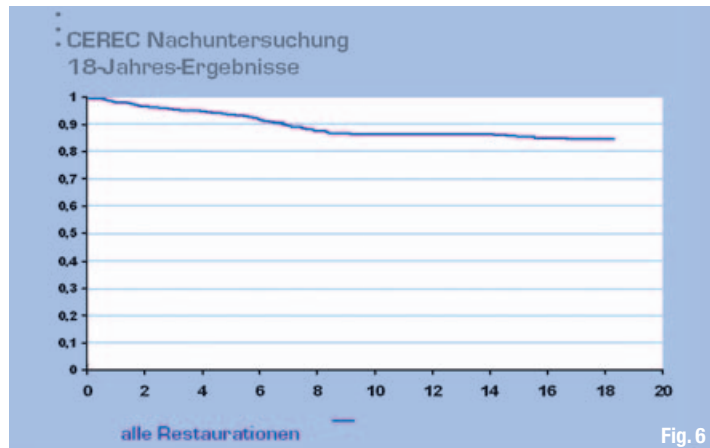


Fig. 6

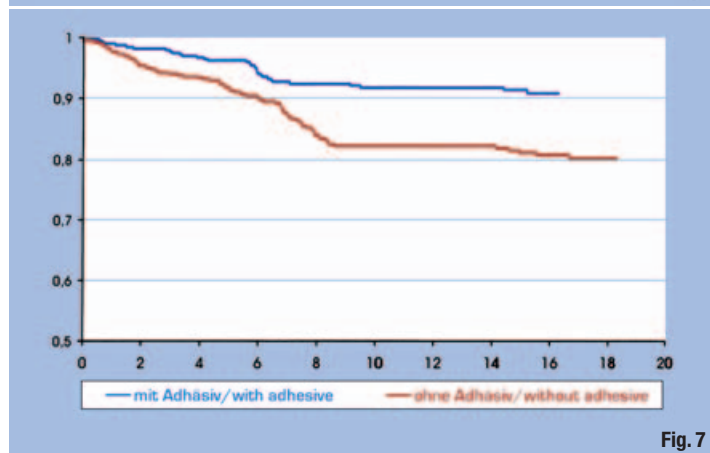


Fig. 7

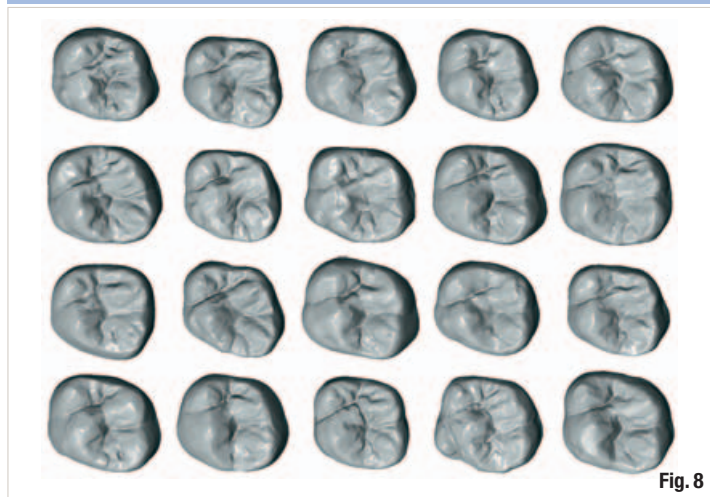


Fig. 8

CAD system. This is followed by the virtual design of the restoration. If required, a 3D working model can be created using a special stereolithography process (SLA). This model provides the basis for the fine tuning of the CAD/CAM-milled crown or bridge framework.

'Impression-free' dentistry offers numerous advantages. The patient does not have to endure the discomfort of a conventional impression (such as gag reflex). In addition, dental laboratories can reduce their production times and achieve significant productivity gains.

Fig. 6 Survival rate of CEREC inlays and onlays: 84.4% overall after 18 years. (Source: Dr Bernd Reiss)

Fig. 7 Survival rate: 90% with dental adhesive; 80% without dental adhesive. (Source: Dr Bernd Reiss)

Fig. 8 Examples of the tooth surfaces contained in the library (here: 6th molar of the upper jaw); at present, approximately 400 tooth surfaces are available for each posterior tooth type. (Illustration: Prof Albert Mehl)

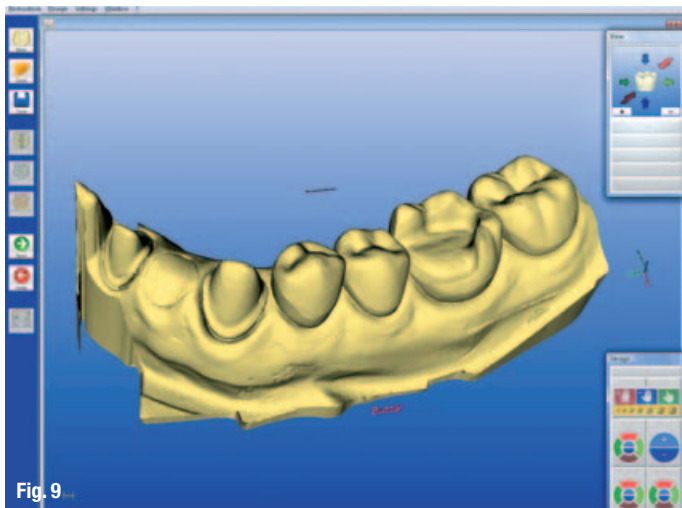


Fig. 9

Fig. 9 The individual images are combined in an anatomically correct way in order to create a virtual quadrant model. (Photo: Dr Andreas Bindl)

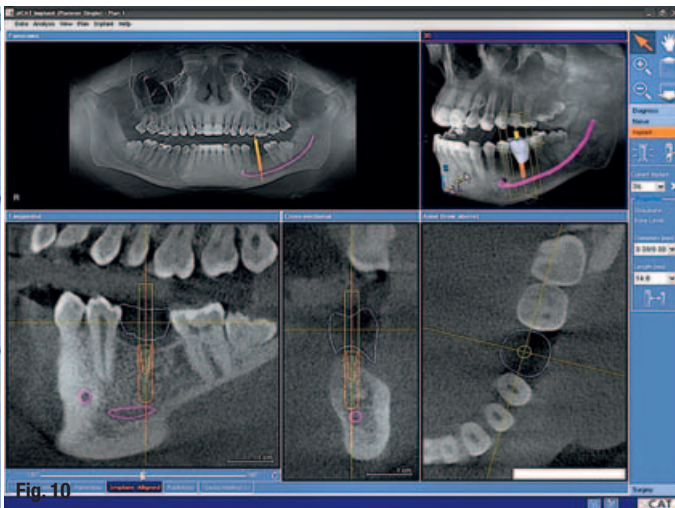


Fig. 10

Fig. 10 CBVT image showing the adjustment of the implant post; the CEREC data record shows the location and insertion axis of the planned crown. (Illustration: Dr Andreas Bindl/Sicat)

_Implant planning with the help of imaging systems

The integration of the CEREC system and cone-beam volumetric tomography (CBVT) enhances the reliability of implant planning. The low-radiation CBVT system generates a detailed 3D image of the bone structure. This ensures greater diagnostic accuracy, as well as the precise localisation of the anatomical structures. CBVT thus provides the basis

reported that anatomically sized, adhesively bonded implant molar crowns (VITA Mark II silicate ceramic) with occlusal wall thicknesses of 1.5 mm have performed well in laboratory tests. This applies to crowns placed on titanium abutments and crowns placed on ZrO₂ abutments.¹⁸

_Summary

CEREC has been transformed from a computer-based 'inlay machine' into a highly versatile system for single-visit dentistry. In future, CEREC will coordinate various functions in dental practices and laboratories. Numerous internationally recognised studies have proved that chairside ceramic inlays and onlays achieve clinical survival rates that are comparable to those of cast-gold restorations. With the introduction of optoelectronic impression-taking for entire quadrants, CEREC has opened the door to impression-free dentistry and has integrated dental laboratories more closely into the work flow of dental practices. CEREC technology has demonstrated to dental professionals that CAD/CAM processes and computer-aided treatment methods will determine the future activities and actions of dental practices and laboratories.



Fig. 11

Fig. 11 Prof Mehler, physicist and biologist (left), has been collaborating closely with Prof Mörmann in Zurich in his role as visiting professor. (Photo: DGCZ/Kern)

for the surgical planning of the implant.¹⁷ The CEREC intra-oral camera is used to scan the implant site and the adjacent teeth. Following this, the software generates a virtual 3D model, on the basis of which the future implant crown is designed and prosthetic planning conducted. The 3D model with the implant crown is then superimposed on the 3D CBVT image. This allows the clinician to position the implant with reference to the planned prosthesis and the available bone structure (Fig. 10).

CEREC is already deployed for the fabrication of implant superstructures. Dr Daniel Wolf et al.

Editorial note: A complete list of references is available from the publisher.

_contact	cosmetic dentistry
<p>Manfred Kern, Wiesbaden, Germany German Society of Computerized Dentistry – International Society of Computerized Dentistry secretariat@dgcz.org www.dgcz.org</p>	